

## Binder's syndrome with Pentalogy of Fallot and anaesthesia

Dr. Battu Lakshmi Prasanna,<sup>1</sup> Dr. Shashank Nilange,<sup>2\*</sup> Dr. Tushar D. Bhavar,<sup>3</sup>

Dr. Akshaya N Shetti<sup>4</sup>

1. Resident, Department of Anaesthesiology and Critical Care, DBVPRMC, PIMS(DU), Loni, Maharashtra, India.
2. Assistant Professor, Department of Anaesthesiology and Critical Care, DBVPRMC, PIMS(DU), Loni, Maharashtra, India.
3. Professor, Department of Anaesthesiology and Critical Care, DBVPRMC, PIMS(DU), Loni, Maharashtra, India.
4. Professor and Head, Department of Anaesthesiology and Critical Care, DBVPRMC, PIMS(DU), Loni, Maharashtra, India.

**\*Corresponding Address:**

Dr. Shashank Nilange, Assistant Professor, Department of Anaesthesiology and Critical Care, DBVPRMC, PIMS(DU), Loni, Maharashtra, India,

E mail id: [shashanknilange@gmail.com](mailto:shashanknilange@gmail.com)

---

### Abstract:

Binder's syndrome is an uncommon congenital facial deformity. It is a rare form of maxillofacial dysplasia with several nasal and mid-face deformities. Binder's syndrome is associated with a difficult airway and difficulty in nasal intubation. Difficult airway carts must be kept ready, both during intubation and extubation. Also, it is associated with mental retardation, cervical spine abnormalities, and dental problems. Pentalogy of Fallot (POF) is a rare form of cyanotic congenital heart disease and is characterized by Tetralogy of Fallot (TOF) with either an Atrial septal defect (ASD) or a Patent Foramen Ovale (PFO). We describe the anaesthetic considerations in the case of Binder's syndrome with Pentalogy of Fallot in a young female patient posted for primary cheiloplasty.

**Key words:** Anaesthetic concerns, Binders Syndrome, Congenital anomaly, Difficult Airway, Maxillofacial dysplasia, Nasal intubation, Pentalogy of Fallot

### Introduction:

Binders syndrome is an uncommon congenital facial deformity. It is a rare form of maxillofacial dysplasia with several nasal and mid-face deformities. Binder's syndrome is associated with a difficult airway and difficulty in nasal intubation. Difficult airway carts must be kept ready, both during intubation and extubation. Also, it is associated with mental retardation, cervical spine abnormalities, and dental problems. Pentalogy of Fallot (POF) is a rare form of cyanotic congenital heart disease and is characterized by Tetralogy of Fallot (TOF) with either an Atrial septal defect (ASD) or a Patent Foramen Ovale (PFO). We describe the anaesthetic considerations in the case of Binder's syndrome with Pentalogy of Fallot in a young female patient posted for primary cheiloplasty.

### Case report:

A 10-year-old female patient weighing 20 kg with Binders syndrome i.e. midline defect involving upper lip, philtrum, columella connecting to intraorally involving alveolus, soft and hard palate since birth posted for primary cheiloplasty (Fig 1a). The patient had complaints of on and off dyspnea on exertion and bluish discoloration since childhood. 2D Echo showed situs solitus levocardia, Patent foramen Ovale present with intermittent right to left shunt large

malaligned subpulmonic Ventricular septal defect with Bi-directional shunt >50% aorta overriding present, severe valvular Pulmonary stenosis for which Bi-directional Glenn surgery was done on 12/10/2022 under General Anesthesia. The patient had normal body temperature with pulse-92/min, Blood pressure-100/60 mmHg, Respiration rate-18/min, Spo2-88-92% on room air. On systemic examination a long, loud, crescendo decrescendo murmur of pulmonary stenosis was audible over the pulmonary area. Chest X-ray - Classic boot-shaped heart with post-thoracotomy sutures noted as shown in figure 1b. 2D ECHO-Situs solitus levocardia, post-Glenn shunt post atrial septectomy, Double outlet right ventricle (DORV) severe pulmonary stenosis max gradient 81 mm hg large Atrial septal defect (L to R shunt), large malaligned sub pulmonary Ventricular septal defect Bi-directional shunt. Routine investigations like Renal function test , liver function test , serum electrolytes , Complete blood picture were within normal limits. Patient was prepared , counselled , and consent was taken . Patient was on Tab. Ecospirin 150 mg BD, Tab. Nicolimalone (citron) 0.5 mg OD (Last dose taken 6 months ago). On airway examination, Mallampatti grade was class 1. The surgeons wanted an oral airway which did not come in their way. Patients was preoxygenated with all precautions of difficult airway, and Glycopyrolate , fentanyl , midazolam were given as premedication. Patient was induced using ketamine , propofol , succinylcholine . On direct laryngoscopy, the modified Cormack and Lehane grading was 1. An oral flexometallic cuffed endotracheal (size 5mm) was inserted and fixed at the center of the lower lip. After confirming bilateral air entry, oropharyngeal or throat packing was done. All standard ASA monitors were instituted. The surgery lasted around three hours and was uneventful. The patient was extubated, after removal of oral packing according to standard protocol, with stable vital parameters handy at the time of extubation also. The patient was observed in the post-anesthesia care unit for six hours, before being shifted to the ward in a stable condition.

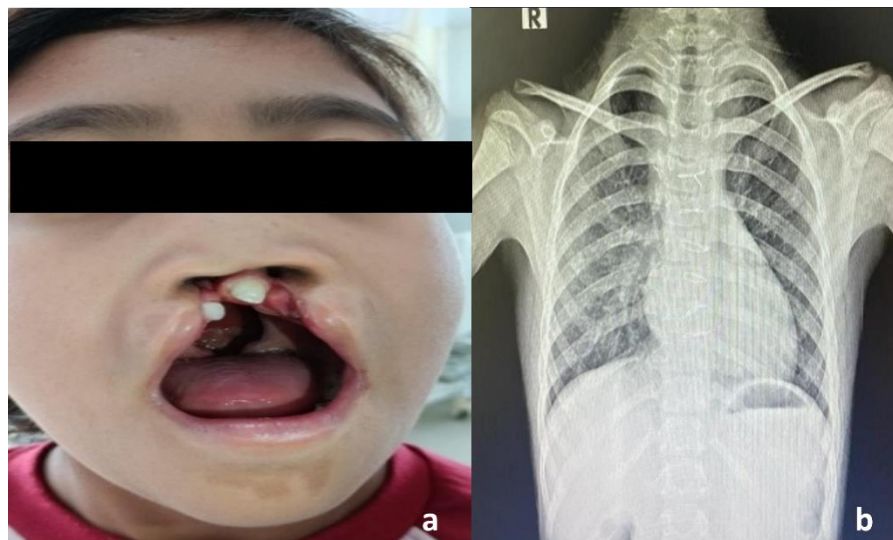


Fig1: a) Midline defect involving upper lip, philtrum, columella b) Classic boot-shaped heart with post-thoracotomy sutures

### Discussion:

Binder's syndrome is an uncommon congenital condition with characteristic facial features. It was identified and defined by Von Binder in 1962, though described earlier by Noyes in 1939.<sup>[1,2]</sup> It is also called "maxilla-nasal dysostosis", with the following six characteristic features: carcinoid face, inter-maxillary hypoplasia (associated with malocclusion), abnormal

position of the nasal bones, nasal mucosal atrophy, anterior nasal spine agenesis and a lack of frontal sinuses. [3] There is a failure of development in the premaxillary area with associated deformities of the nasal skeleton and overlying soft tissues like unusually flat, underdeveloped midface, abnormally short nose and flat nasal bridge, underdeveloped upper jaw, relatively protruding lower jaw requiring staged plastic and reconstructive surgery. [4] Other associated features include mental retardation, bilateral hearing loss, prenatal vitamin K deficiency, irregularities in the cervical spine, prominent lips, poor oral dental hygiene, and psychological problems due to cosmetic defects. According to Holmstrom, the inheritance of this syndrome may be an autosomal recessive trait with incomplete penetrance. [5,6] These patients present for surgical correction of facial deformities and orthodontic treatment of dental problems. The main surgery performed is a nasal reconstruction with bone or cartilage grafts. [7] Others include maxillary protraction with rapid palatal expansion. Patients can present for repeated surgeries due to graft resorption or an unsatisfactory appearance. The main anaesthetic consideration is the presence of a difficult airway. Nasal intubation should not be attempted in these patients due to reduced nasal passages and the possibility of trauma during tube passage. [8,9] Insertion of a nasogastric tube can be difficult. Direct laryngoscopy must be gentle and cautious due to dental malocclusion and crowding. Complete difficult airway cart must be prepared and checked preoperatively. Pre-anaesthetic assessment should be done for associated abnormalities with Binder's syndrome. An otorhinolaryngologist evaluation, cervical spine X-rays, psychological counseling, dental opinion, and measures to improve oral hygiene are vital in the preoperative period. If airway assessment is otherwise normal, a video-laryngoscopic guided oral intubation can be done after intravenous and/or inhalational induction, with the muscle relaxant given after confirming the correct tube position. A wire-reinforced tracheal tube is preferable to prevent its kinking during head and neck movements during surgery. Endotracheal tube fixation requires special attention as it should not come in the way of the surgical field and at the same time does not cause a drag on the angles of the mouth. Secure tube fixation at the center of the lower lip may be preferred to help the surgeon assess the symmetry of the mid-face during reconstruction. Oral packing may be done to prevent blood and secretions from trickling into the lower airway during surgery. Care must be taken in documenting the use of oro-pharyngeal packs (with a radio-opaque line) and remembering to remove them at the end of surgery. Since osteotomy and grafts are required for the surgery, Perioperative blood should be estimated and transfusion should be given accordingly. Temperature maintenance (normothermia) must be ensured, especially in prolonged procedures with the help of patient and fluid warmers. Difficult airway precautions must be followed at the time of extubation as well, including tube exchanger device. The goal of anesthesia in the pentalogy of Fallot patients should be aimed at maintaining normovolemia, preventing hypoxemia, avoiding a decrease in SVR and increase in PVR, and maintaining contractility of the heart. Avoid hypercarbia, acidosis, hyperthermia, pain, and inadequate depth of anesthesia. Consider appropriate size for monitoring NIBP and invasive pressure monitoring, if required. Postoperatively appropriate analgesia reduces stress on the child and hence reduces cyanotic spells. Most importantly, the attending anesthesiologist must be aware of this rare syndrome and its associated anomalies to improve the overall perioperative outcome of the affected patients. This case was reported to improve the knowledge bank of the anesthesiologists worldwide, to handle such cases effectively.

## Conclusion:

Binder's syndrome, though rare, must be kept in mind while anesthetizing a patient for faciomaxillary reconstructive surgery. A thorough pre-operative evaluation for concurrent conditions and a complete airway assessment is of paramount importance. Since these patients can present for several staged procedures, multiple anaesthetic exposures are a possibility, especially in a scenario of a difficult airway. Awareness of this rare syndromic disorder enables the anesthesiologist to prepare the operation theatre adequately and to manage the associated problems successfully.

## Reference:

1. Venkatesh A, Anuradha B, Karthick A, Chandramouli PE, Ramasamy M. Binder's Syndrome - A rare case report and review of the literature with a detailed treatment plan. *Biomed. and Pharmacol. J.* 2016;9(3):1049-1055
2. Von Binder KH. Dysostosis maxilla-nasalis, ein arhinen- cephaler Missbildungskomplex. *Deustsch Zahnaertzl Z* 1962;17:438
3. Dyer FMV, Willimot DR. Maxillo-nasal dysplasia, Binder's syndrome: a review of the literature and case report. *J Orthod.*2002;29:15-21
4. Jain U, Thakur G, Kallury A. Binder's syndrome. *BMJ Case Reports* 2011;10.1136/bcr.08.2011.4665
5. Olow-Nordenam M, Radberg CT. Maxillonasal dysplasia (Binder Syndrome) and associated malformations of the cervical spine. *Acta Radiol Diagn.* 1984;25:353-360
6. Holmstrom H. Clinical and pathologic features of mail-nasal dysplasia (Binder's syndrome): significance of the prenasal fossa on etiology. *Plast Reconstr* 1986;78:559-67
7. Bhatt YC, Vyas KA, Tandale MS, Panse NS, Bakshi HS, Shri- Srivastava RK. Maxillonasal dysplasia (Binder's syndrome) and its treatment with costal cartilage graft: A follow-up study.
8. White MC, Peyton JM. Anaesthetic management of children with congenital heart disease for congenital heart non-cardiac surgery. *Contin Educ Anaesthesia, Grit Care Pain.* 2012;12(1):17-22.
9. Menghrai 5J. Anaesthetic considerations in children with congenital heart disease undergoing non-cardiac surgery. *Indian J Anaesth,* 2012;56(5):491-495.

**Submitted:** 28/12/2023

**Revised:** 03/01/2024

**Accepted:** 10/12/2023

**Published:** 26/01/2024

### Cite this article:

Dr. Battu Lakshmi Prasanna, Dr. Shashank Nilange, Dr.Tushar D. Bhavar, Dr. Akshaya N Shetti. Binder's syndrome with Pentalogy of Fallot and anaesthesia. *Jour Med Dent Fron* 2024; 1(1):47-50